

# Utility of Computerized Isocentric Fluoroscopy for Minimally Invasive Spinal Surgical Techniques

Alan T. Villavicencio, MD,\* Sigita Burneikiene, MD,\* Ketan R. Bulsara, MD,†  
and Jeffrey J. Thramann, MD\*

**Objective:** The purpose of this study was to prospectively evaluate the clinical utility and accuracy of intraoperative three-dimensional fluoroscopy as an adjunct for the placement of a complex spinal instrumentation.

**Methods:** The Siemens Iso-C three-dimensional fluoroscopy unit in the combination with the Stealth Treon computer volumetric navigational system was used. A total of 279 spinal instrumentation screws or transpedicular cannulations were performed in 69 patients. Accuracy, operative time, and amount of fluoroscopy utilization time were assessed for transforaminal lumbar interbody fusion (TLIF) and kyphoplasty cases.

**Results:** Only 4 percutaneous transpedicular lumbar screws out of 265 total (1.5%) were malpositioned. Average operative time for TLIF cases was 185 minutes (range 114–311 minutes) for one-level and 292.6 minutes (range 173–390 minutes) for two-level procedures. Biplanar fluoroscopy utilization time was 93 seconds (range 27–280 seconds) for one-level procedures and 216 seconds (range 80–388 seconds) for two-level procedures. Average surgery duration for kyphoplasty was 60 minutes (range 36–79 minutes) for one-level procedures and 68.5 minutes (range 65–75 minutes) for two-level cases. Biplanar fluoroscopy utilization time was 41.3 seconds per case (range 25–62 seconds).

**Conclusions:** Use of intraoperative three-dimensional fluoroscopy for image guidance in minimally invasive complex spinal instrumentation procedures is feasible and safe. This technique provides excellent visualization of three-dimensional relationships. This potentially results in improved accuracy of screw positioning and the ability to detect misplaced screws prior to wound closure. This technique also potentially results in a significant reduction in radiation exposure for both the patient and the staff.

**Key Words:** 3-D fluoroscopy, image guidance, iso-C, spine surgery  
(*J Spinal Disord Tech* 2005;18:369–375)

Received for publication February 10, 2005; accepted April 21, 2005.  
From \*Boulder Neurosurgical Associates, Boulder, CO, and †University of Missouri, Columbia, MO.  
Supported by the Justin Parker Neurosurgical Research Fund.  
Reprints: Dr. A.T. Villavicencio, Boulder Neurosurgical Associates, 1155 Alpine Ave., Suite 320, Boulder, CO 80304 (e-mail: atv@bnasurg.com).  
Copyright © 2005 by Lippincott Williams & Wilkins

Reduced visualization of the operative field in minimally invasive surgery requires higher accuracy. The unreliability of the routine two-dimensional fluoroscopy in assessing pedicle screw placement has been previously demonstrated. Based on these studies, the rate of penetration of the pedicle cortex by an inserted screw ranges from 5% to 41% for open lumbar spine cases.<sup>1–8</sup> Weinstein et al<sup>9</sup> revealed limitations of two-dimensional fluoroscopy in an in vitro study. They reported a 21% incidence of pedicle screw malpositioning, 92% of perforations being medial. This was confirmed in clinical studies. Castro et al<sup>7</sup> revealed 40% misplacement, 71.4% perforations being medial. Introduction of image guidance technology has significantly altered previously mentioned rates. These vary from 0% to 9%.<sup>5,10–14</sup> Unfortunately, computed tomography (CT)-based surgical navigation requires time-consuming intraoperative point-to-point registration steps and preoperative planning that introduces an inherent amount of error into the system.

Standard intraoperative fluoroscopy lacks the ability to reconstruct three-dimensional images. There are no axial images available intraoperatively, frequently resulting in the need to constantly reposition the C-arm and take more frequent images, with increased radiation exposure. These drawbacks associated with conventional fluoroscopy have led to the development of Iso-C fluoroscopy units such as the Siremobil Iso-C three-dimensional fluoroscopy (Siemens Medical Solutions, Erlangen, Germany), which allows acquisition of axial, sagittal, and coronal images and produce three-dimensional reconstructions. This prospective, nonrandomized cohort study evaluates the feasibility and accuracy of using intraoperative three-dimensional fluoroscopic guidance for placement of hardware in complex spinal procedures.

## MATERIALS AND METHODS

Placement of 265 spinal instrumentation screws and 14 transpedicular kyphoplasty procedures were performed using Iso-C three-dimensional fluoroscopic navigation between July 2003 and September 2004. Forty-five patients (63.4%) were female and twenty-four (36.6%) were male. Average age of the patients was 55.2 years (range 19–99 years).

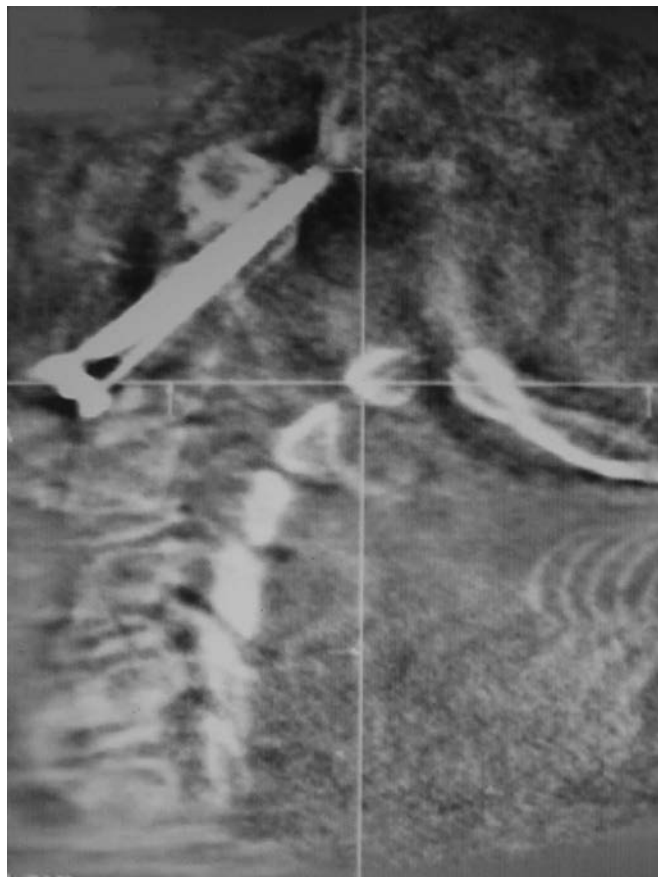
Patient data, including preoperative and postoperative evaluations, were collected on a prospective basis. Thirty-six patients (52.2%) underwent interbody fusion with percutaneous pedicle screws for discogenic pain. Fifteen patients were treated for spinal fractures: Eleven patients (15.9%) were treated with kyphoplasty procedures for pathologic compression-type fractures, three patients (4.3%) were treated

for type II odontoid fractures, and one patient (1.5%) was treated with C2 pedicle screws and C3 lateral mass screws. Eighteen patients (26.1%) underwent surgery for spinal instability. Patients with discogenic pain were selected for surgery based on a history of mechanical symptoms and failed conservative treatment.

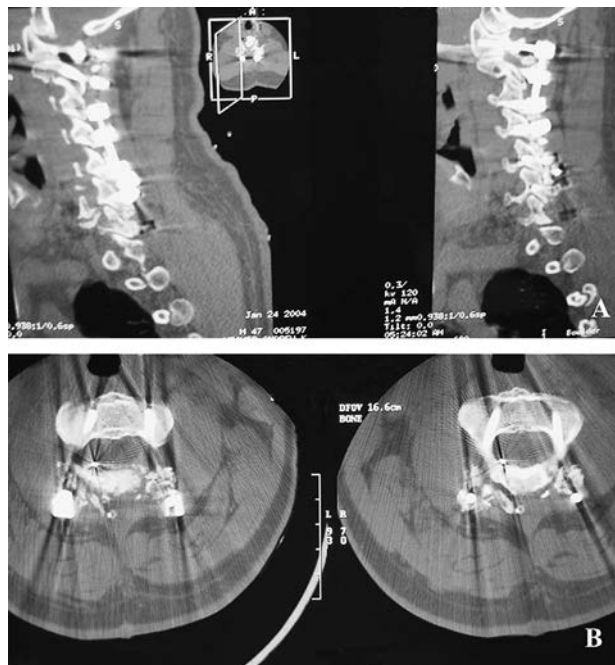Biplanar fluoroscopy exposure time and operative time were assessed for transforaminal lumbar interbody fusion (TLIF) and kyphoplasty procedures. Accuracy of screw placement was evaluated on intraoperative Iso-C fluoroscopy images (Fig. 1) and verified on thin-slice (1- to 1.5-mm) postoperative helical CT scans (Fig. 2A-B). Because of the small numbers, statistical analysis was not performed for other procedures such as Magerl and odontoid screws, cervical lateral mass, or C2 pedicle screw placement.

Any penetration of the screw was measured in millimeters using the CT scan image scale. A four-group classification was used: 0–2, 2–4, 4–6, and 6–8 mm. Localization of the violation was also noted.

Fine-cut postoperative helical CT scans were obtained postoperatively to evaluate the accuracy of the image guidance (see Fig. 3). This included confirming the position of the implants for instrumentation cases and assessing the path of the trocar and position of bone cement for kyphoplasty cases.



**FIGURE 1.** Isocentric fluoroscopy image verifying good positioning of odontoid screw intraoperatively prior to wound closure.

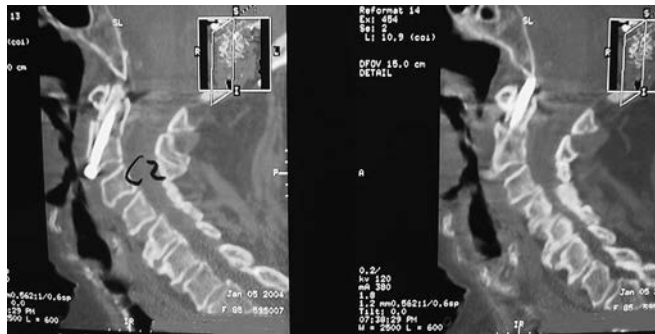

**FIGURE 2.** A, Postoperative sagittal CT three-dimensional reconstruction demonstrating good positioning of C1 lateral mass screw and C2 pedicle screw on the right. B, Postoperative axial CT three-dimensional reconstruction demonstrating good positioning of C2 lateral mass screws.

### Surgical Procedures

Two hundred twenty percutaneous pedicle screws were placed in 46 patients undergoing TLIF. Twenty-eight patients (60.9%) underwent surgery for a single level: 12 (42.8%) at L5–S1, 10 (35.7%) at L4–L5, 4 (14.3%) at L3–L4, 1 (3.6%) at L1–L2, and 1 patient (3.6%) at L2–L3. Eighteen patients (39.1%) had surgery on two levels: 15 (83.3%) at L4–L5 and L5–S1, 2 (11.1%) at L3–L4 and L4–L5, and 1 patient (5.6%) at L2–L3 and L3–L4.

Eleven patients with pathologic compression fractures underwent percutaneous kyphoplasty procedures. Eight patients (72.7%) had a single fractured level, whereas three patients (27.3%) had vertebral fractures at two levels. Ten patients



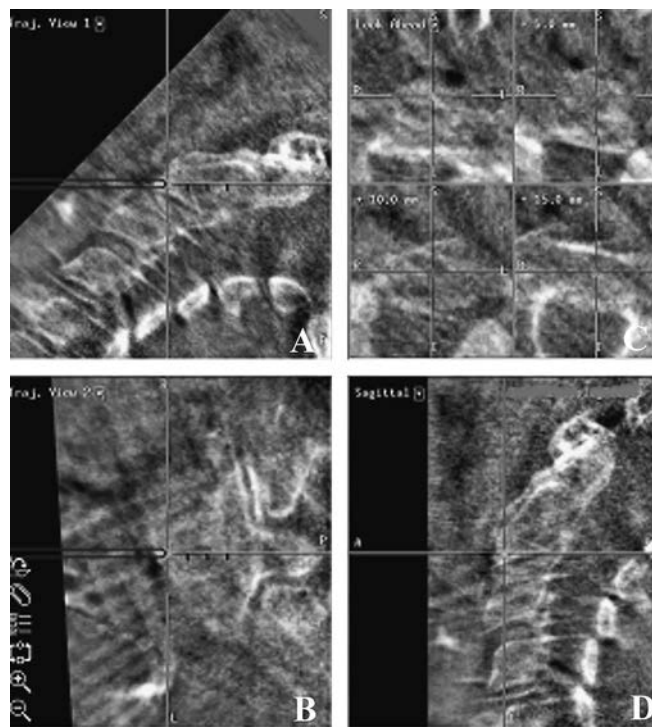
**FIGURE 3.** Postoperative fine-cut spiral CT three-dimensional reconstruction confirming screw position.

(90.9%) had primary osteoporotic vertebral compression, and one (9.1%) was treated for osteolytic metastatic disease. Three lumbar (L1–L5) and 11 thoracic (T4–T12) kyphoplasty procedures were performed.

C2 odontoid screws were placed in three patients with type II odontoid fractures. Two patients with atlantoaxial instability had C1–C2 transarticular (Magerl) screws placed. Three patients underwent subaxial cervical lateral mass fixation performed on three, four, and six levels, respectively. A total of 32 subaxial cervical lateral mass screws were placed. Two patients had C1 lateral mass fixation (four screws) and two patients had C2 pedicle screws (four screws). Table 1 summarizes the total number of screws placed.

### Technique

After localization of the appropriate levels with standard fluoroscopy using the Iso-C unit, a dynamic reference array was attached to an adjacent-level spinous process for registration. No surgeon-dependent registration step was required. The registration process is automated. The Siemens Iso-C three-dimensional fluoroscopy unit acquires intraoperative images while the C-arm is rotating in the angular and orbital directions, with the center focus precisely maintained. There is no need to adjust the unit when switching between anteroposterior and lateral views. The C-arm functions concurrently as a regular fluoroscopy unit, while also allowing for the three-dimensional reconstruction of images into axial, sagittal, and coronal planes (Figs. 4 and 5) by acquiring 100 two-dimensional images through an Iso-C 190° rotation. Reconstructed three-dimensional volumes of 256 isotropic pixel images are transferred to the Stealth Station Treon Treatment Guidance System (Medtronic, Louisville, CO). An integrated navigation interface NaviLink was used for direct connection to navigation systems. It took approximately 2 minutes to



**FIGURE 4.** A, Sagittal reconstruction trajectory view of upper cervical spine illustrating the C2 fracture and trajectory of the surgical approach. B, Coronal trajectory view. C, “Look-ahead” view demonstrating the trajectory of the probe into C2 where the green cross-hairs represent the location of the probe projecting forward along its current angle. D, True sagittal view taken through the location of the tip of the probe.

acquire the images and another 60 seconds for the three-dimensional reconstructions.

All pedicle screws were inserted using Iso-C fluoroscopy image guidance. Standard two-dimensional fluoroscopy was used to localize the appropriate spinal levels for pedicle screw placement (see Fig. 6, A and B) and in kyphoplasty procedures prior to placement of the dynamic reference array.

## RESULTS

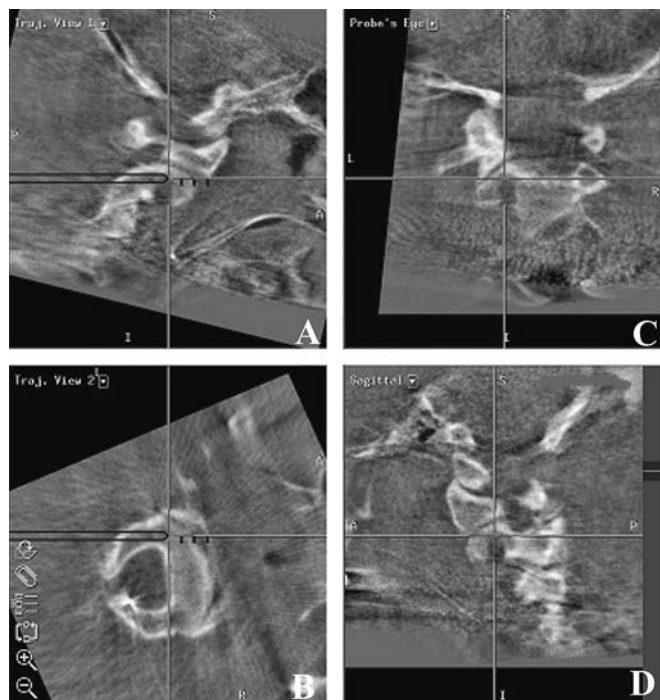
### Operative Data and Biplanar Fluoroscopy Time

Average operative time for one-level procedures was 185 minutes (range 114–311 minutes) and 292.6 minutes (range 173–390 minutes) for two-level percutaneous TLIF procedures. Average duration of surgery for one-level kyphoplasty procedures was 60 minutes (range 36–79 minutes) and for two-level cases 68.5 minutes (range 65–75 minutes) (Table 2).

Average biplanar fluoroscopy utilization time (see Table 2) with Iso-C fluoroscopy-assisted cases was 93 seconds (range 27–280 seconds) for one-level TLIF procedures and 216 seconds (range 80–388 seconds) for two-level TLIF procedures. For kyphoplasty procedures, this averaged 41.3 seconds per case (range 25–62 seconds). There was another 40 seconds of fluoroscopy time during the initial “spin” and the intraoperative “spin” to verify good screw placement.

**TABLE 1.** Surgical Procedures and Misplaced Screw Rates

Procedure	Levels	Patients	Screws	Misplaced
One-level TLIF				
	L5–S1	12	48	None
	L4–L5	10	40	None
	L3–L4	4	16	None
	L1–L2	1	4	None
	L2–L3	1	4	None
	Total	28	112	None
Two-level TLIF				
	L4–L5, L5–S1	15	90	3 (3.3%)
	L3–L4, L4–L5	2	12	1 (8.3%)
	L2–L3, L3–L4	1	6	None
	Total	18	108	4 (3.7%)
Odontoid screws	C2	3	3	None
C1–C2 Magerl screws	C1–C2	2	2	None
Subaxial cervical lateral mass screws	C1–C7	3	32	None
C2 pedicle screws	C2	2	4	None
C1 lateral mass screws	C1	2	4	None
Total		58	265	4 (1.5%)

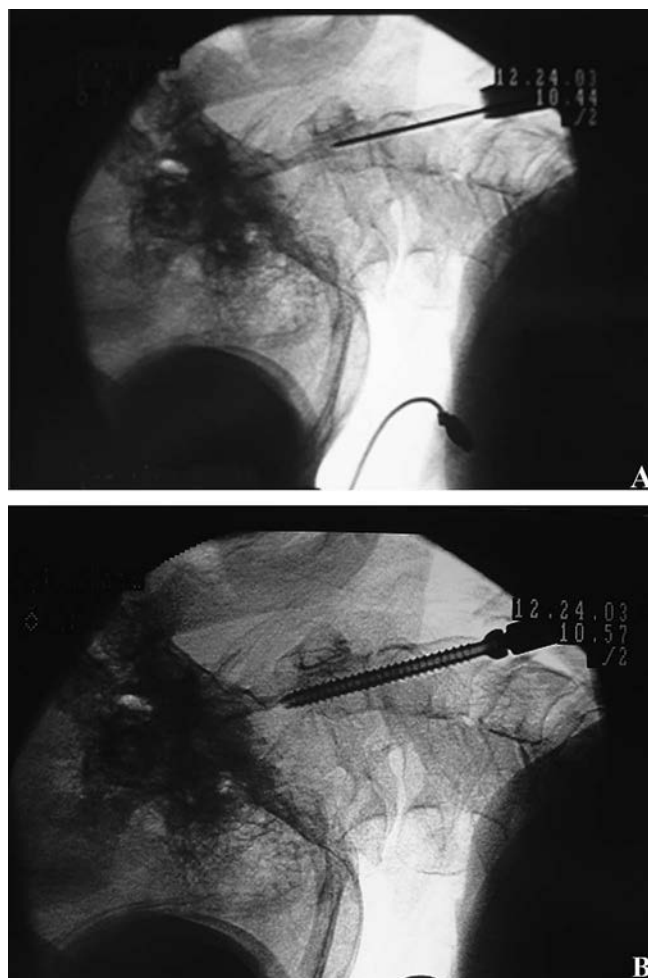


**FIGURE 5.** A, Sagittal reconstruction trajectory view of upper cervical spine illustrating the surgical approach and trajectory of the probe for a C2 pedicle screw. B, Coronal reconstruction trajectory view. C, “Probe’s eye” view demonstrating the trajectory of the probe into C2 where the green cross-hairs represent the location of the probe projecting forward along its current angle. D, True sagittal view taken through the location of the tip of the probe.

**Accuracy Assessment and Complications**

There were no misplaced screws in the odontoid, C1–C2 Magerl, lateral mass, C2 pedicle screw, or one-level TLIF patient groups. All pedicles were cannulated without difficulty in the percutaneous kyphoplasty group. Four patients (1.5%) had misplaced pedicle screws in the two-level minimally invasive TLIF group. One patient had 6-mm (grade III) medial pedicle screw perforation at L5 and underwent reoperation for removal of the screw 1 day after the original surgery. In this case, a postoperative verification “spin” was not performed. Another patient had 5-mm lateral perforation (grade III) at L4, which was identified by a second Iso-C fluoroscopy “spin” intraoperatively, and the screw was repositioned accordingly. For two patients, a slight cortical breach (grade I) was identified intraoperatively, but it was elected to leave pedicle screws in place based on the size of the pedicles and because there was <2 mm of lateral perforation (see Table 1). These findings as well as screw placement within the cortical margins were confirmed by the postoperative helical CT scans.

Other complications included postoperative hematomas in 2 of 69 patients (2.9%); 2 patients were treated for new postoperative radiculopathy (2.9%). Two patients had postoperative numbness and dorsiflexion weakness that resolved within 3 months of surgery. One patient (1.4%) developed a seroma 10 days after the surgery, which was negative to any



**Figure 6.** A, Lateral fluoroscopic image illustrating placement of K-wire. B, Lateral fluoroscopic image of screw being inserted over K-wire.

bacterial pathogens. Lumbar paraspinal fluid aspiration was performed. One patient with severe cervical spondylotic myelopathy died 3 days following surgery as a result of severe coronary artery disease and acute renal failure.

**DISCUSSION**

Conventional techniques for placement of pedicle screws are based primarily on intraoperative anatomic landmarks and preoperative imaging studies. However, anatomic landmarks vary considerably not only among different individuals with

**TABLE 2.** Operative Data and Biplanar Fluoroscopy Time for TLIF and Kyphoplasty Procedures

Procedure	Operative Time (min)	Biplanar Fluoroscopy Time (s)
One-level TLIF	185 (114–311)	93 (27–280)
Two-level TLIF	292.6 (173–390)	216 (80–388)
Kyphoplasty	64.3 (36–79)	41.3 (25–62)

normal spinal anatomy, but especially in patients with scoliosis, degenerative spondylolisthesis, and osteoarthritis where variable transformations in the facet joint and pedicle axis orientation are present.<sup>15</sup> Image guidance technologies bring the surgeon closer to the ideal starting point and trajectory, therefore increasing accuracy. With the recent development of minimally invasive surgical techniques, where anatomic landmarks cannot be visualized, image guidance is essential.

The inability to obtain axial and sagittal reconstructed images remains the main limitation of using conventional fluoroscopy for intraoperative image guidance. This increases the potential for pedicle screw violation and neural injury. Theoretically, repeated fluoroscopic images need to be taken to verify instrument or implant position, which increases radiation exposure to the patient and operative room personnel. Repositioning and adjusting the C-arm during the surgical procedure to obtain adequate views can be cumbersome, and it can be difficult to maintain sterility. Although CT and magnetic resonance imaging have the capacity to obtain axial images, neither of these imaging modalities is suitable for routine use in the operating room.<sup>16</sup> Iso-C fluoroscopy provides as close as there is to real-time image guidance. Preoperative CT-based image guidance does not allow for anatomic changes as they occur during positioning of the patient intraoperatively, and updated real-time images are not available.

Iso-C fluoroscopy employs axial, coronal, and sagittal reconstructed images, real-time navigation, automated registration, and intraoperative postinstrumentation evaluation. These intraoperative “verification of screw placement images” often eliminate the need for the follow-up radiologic examination and ensure proper placement of instrumentation prior to the patient leaving the operating room.

### Accuracy

In a recent clinical study, a 1.7% pedicle screw misplacement rate was reported using isocentric fluoroscopy.<sup>17</sup> Our reported incidence of 1.5% is consistent with this. In addition, all screw malpositions in this series occurred during the first 16 cases and the initial 3 months of using Iso-C fluoroscopy for intraoperative image guidance. A 0% rate of misplaced screws in the lumbar and 8% in the thoracic spine were reported in experimental settings<sup>10</sup> where percutaneous screw placement was performed in cadaveric specimens using Iso-C. Five violations (8%) occurred in the 64 thoracic spine pedicles.

Clinical and experimental studies have been performed evaluating the accuracy of pedicle screw insertion with and without navigation.<sup>5,18–20</sup> Laine et al<sup>5</sup> reported increased surgical time and decreased pedicle perforation rate in the image-guided surgical procedure group (4.6%) compared with a conventional group (13.4%). Similar results were confirmed by Amiot et al<sup>18</sup> with a total pedicle screw misplacement rate in the conventional group of 15% (83/544). However, 18% (15/83) of all misplaced pedicle screws violated pedicle by >2.1 mm. Seven patients required redo surgery in this group because of postoperative neurologic deficits.

Not all cortical violations are symptomatic. Castro et al<sup>7</sup> postulated that with a penetration of the screw into the spinal canal of  $\geq 6$  mm, a neurologic deficit is likely to occur. Based

on this, some authors argue that intraoperative image guidance is unnecessary and only leads to increased costs and operative time. Rates of neurologic deficit after spinal surgery with instrumentation vary from 0.5% to 16.6%.<sup>2,7,8,21–23</sup> However, violations of the cortical bone can weaken biomechanical construct,<sup>24</sup> even if they are asymptomatic.

Hott et al<sup>25</sup> evaluated Iso-C fluoroscopy data and its concurrence with postoperative CT studies. Six percent (2/33) of the screws violated the margin of the pedicle wall by <2 mm and were successfully identified in intraoperative Iso-C fluoroscopic evaluation. Wang et al<sup>24</sup> compared the reliability of conventional CT and three-dimensional fluoroscopy in a human cadaver spine model for assessing pedicle violations. Iso-C fluoroscopy was slightly more sensitive but less specific than conventional CT scans; 28.4% of pedicle violations were not detected, and 21.1% were incorrectly determined as misplaced. Higher-grade violations (>4 mm) were detected 100% of the time with Iso-C fluoroscopy. In our study, we performed Iso-C fluoroscopy immediately at the end of the surgery followed by postoperative helical CT scans for verification of accuracy. Three cases of pedicle screw misplacement were identified correctly, and one was not recognized using Iso-C fluoroscopy and required reoperation. This is related to the fact that a second “verification” spin was not performed in this case. If this had been performed, it is likely that the cortical breach would have been identified and corrected, thus saving the patient a second trip to the operating room. The calculated accuracy rate of pedicle screw placement using Iso-C three-dimensional fluoroscopy in our study was 98.5%, which favorably compares with the previously reported results.<sup>10,17,25</sup> A definite learning curve was observed, in which all reported complications occurred during the first 16 cases and the initial 3 months of use.

Registration of most types of the existing navigational devices is based on anatomic landmarks. The greatest degree of inaccuracy in the procedure is added by the registration process.<sup>12,26,27</sup> The registration process using Iso-C fluoroscopy navigation is automated. No manual registration is involved. By eliminating this requirement, a higher degree of accuracy is theoretically achieved. Choi et al (unpublished data, 2003) measured the root mean square registration accuracy for Iso-C fluoroscopy in the clinical setting, which averaged 1.1 mm (range 0.8–2.3 mm). According to Rampersaud et al,<sup>28</sup> the highest degree of accuracy is required at the midcervical, midthoracic, and thoracolumbar junction regions, with a translational error of <1 mm and rotational error of <5°.

### Radiation Exposure

The Iso-C three-dimensional fluoroscopy unit acquires intraoperative images while the C-arm is rotating in the angular and orbital directions, with the center focus precisely maintained. This design eliminates the need to readjust the C-arm’s horizontal or vertical travel when changing between anteroposterior and lateral positions. Thus, positioning is quick and easy, potentially saving time. Although Iso-C three-dimensional fluoroscopy does not completely eliminate the subsequent need for conventional fluoroscopic images, its overall effect is to decrease the amount of radiation exposure to both the patient and the operating room personnel, while at the

same time provide improved image guidance. The dose associated with the initial 2-minute “spin” for Iso-C fluoroscopy is 0.75 times lower than for standard two-dimensional fluoroscopy, therefore a 120-second “spin” is equivalent to 30 seconds of standard two-dimensional fluoroscopy. The surgical team does not even have to be in the same room as the patient during the acquisition phase of the image guidance process. In addition to the 40 seconds of fixed radiation time during 120 seconds of intraoperative “spin,”<sup>25,29</sup> 93 seconds of biplanar fluoroscopy time was used on average for one-level TLIF, 216 seconds for two-level TLIF, and 41 seconds for kyphoplasty procedures. Choi et al (unpublished data, 2003) reported 66 seconds’ average (range 30–126 seconds) of fluoroscopy time for pedicle screw placement in lumbar, thoracic, and cervical spine. Fifty-eight pedicles in 14 consecutive patients were instrumented at the University of Colorado Hospital using this technique. Two patients with cervical, 1 with thoracic, and 11 with lumbar pathologies were included in this series. Grutzner et al<sup>17</sup> used  $88 \pm 56$  seconds of fluoroscopy time for 302 pedicle screws placed in 61 patients (4.9 screws per patient).

The main limitation of our study was that it was nonrandomized and we did not have a control group to compare operative data and biplanar fluoroscopy time for the cases where Iso-C image guidance was not used. Gebhard et al<sup>29</sup> compared the dose of radiation exposure for surgical procedures performed with and without image guidance using CT-based navigation, conventional C-arm navigation, and Iso-C navigation. The lowest emission of ionizing radiation was for navigation with the Iso-C method. Average fluoroscopy times were reported for the different procedures: 180 seconds for conventional fluoroscopy, 79 seconds for CT-based navigation, 91 seconds for C-arm-based navigation, and 20 seconds for Iso-C-based navigation.

## Operative Time

Foley et al<sup>30</sup> reported 240 minutes’ average operative time for minimally invasive TLIF cases using biplanar fluoroscopy, which would compare with 238.8 minutes’ average time for all cases or 185 minutes’ time for one-level and 292.6 minutes for two-level cases in this study. The average operative duration using intraoperative three-dimensional navigation reported by Grutzner et al<sup>17</sup> was  $103.26 \pm 23.3$  minutes. Three hundred two pedicle screws were placed in 61 patients (4.9 screws per patient). No information was given on what kind of screws was used or whether this was the total time per surgery or just screw placement.

## Limitations

Image quality is directly related to the amount of artifact generated by any type of metal in the field of view, including any metallic implants.<sup>24</sup> Image quality could potentially be suboptimal for obese patients, and it has been reported that some morbidly obese patients do not fit into the C-arm.<sup>24,25</sup> In our experience, we have not encountered either of these problems. Another potential limitation involves the fact that the image volume during the spin is limited to about four spinal levels, depending on the size of the patient. Additional

“spins” might therefore be occasionally required for long constructs.<sup>25</sup>

## CONCLUSION

This study demonstrates that use of Iso-C three-dimensional fluoroscopy for intraoperative image guidance in minimally invasive complex spinal instrumentation procedures is feasible and safe. Based on our rates of malpositioned screws, this technique seems to provide improved visualization over the standard fluoroscopy of three-dimensional relationships, which results in an increased accuracy of screw positioning and the potential to detect misplaced screws prior to wound closure. This technique also seems to result in a reduction of radiation exposure. We believe that these advantages justify the increased cost of acquiring the equipment. Further randomized comparison with conventionally used fluoroscopy systems would be needed to more critically evaluate the improved accuracy of this technique.

## REFERENCES

- George DC, Krag MH, Johnson CC, et al. Hole preparation techniques for transpedicle screws. Effect on pull-out strength from human cadaveric vertebrae. *Spine*. 1991;16:181–184.
- Esses SI, Sachs BL, Dreyzin V. Complications associated with the technique of pedicle screw fixation. A selected survey of ABS members. *Spine*. 1993;18:2231–2239.
- Jutte PC, Castelein RM. Complications of pedicle screws in lumbar and lumbosacral fusions in 105 consecutive primary operations. *Eur Spine J*. 2002;11:594–598.
- Odgers CJ 4th, Vaccaro AR, Pollack ME, et al. Accuracy of pedicle screw placement with the assistance of lateral plain radiography. *J Spinal Disord*. 1996;9:334–338.
- Laine T, Lund T, Ylikoski M, et al. Accuracy of pedicle screw insertion with and without computer assistance: A randomised controlled clinical study in 100 consecutive patients. *Eur Spine J*. 2000;9:235–241.
- Laine T, Makitalo K, Schlenzka D, et al. Accuracy of pedicle screw insertion: A prospective CT study in 30 low back patients. *Eur Spine J*. 1997;6:402–405.
- Castro WH, Halm H, Jerosch J, et al. Accuracy of pedicle screw placement in lumbar vertebrae. *Spine*. 1996;21:1320–1324.
- Schulze CJ, Munzinger E, Weber U. Clinical relevance of accuracy of pedicle screw placement. A computed tomographic-supported analysis. *Spine*. 1998;23:2215–2221.
- Weinstein JN, Spratt KF, Spengler D, et al. Spinal pedicle fixation: Reliability and validity of roentgenogram-based assessment and surgical factors on successful screw placement. *Spine*. 1988;13:1012–1018.
- Holly LT, Foley KT. Three-dimensional fluoroscopy-guided percutaneous thoracolumbar pedicle screw placement. Technical note. *J Neurosurg*. 2003;99(suppl 3):324–329.
- Merloz P, Tonetti J, Pittet L, et al. Computer-assisted spine surgery. *Comput Aid Surg*. 1998;3:297–305.
- Kalfas IH, Kormos DW, Murphy MA, et al. Application of frameless stereotaxy to pedicle screw fixation of the spine. *J Neurosurg*. 1995;83:641–647.
- Ebmeier K, Giest K, Kalff R. Intraoperative computerized tomography for improved accuracy of spinal navigation in pedicle screw placement of the thoracic spine. *Acta Neurochir [Suppl]* 2003;85:105–113.
- Girardi FP, Cammisa FP Jr, Sandhu HS, et al. The placement of lumbar pedicle screws using computerised stereotactic guidance. *J Bone Joint Surg Br*. 1999;81:825–829.
- Robertson PA, Novotny JE, Grobler LJ, et al. Reliability of axial landmarks for pedicle screw placement in the lower lumbar spine. *Spine*. 1998;23:60–66.
- Hazan EJ. Computer-assisted orthopaedic surgery: A new paradigm. *Tech Orthop*. 2003;18:221–229.
- Grutzner PA, Beutler T, Wendl K, et al. [Intraoperative three-dimensional navigation for pedicle screw placement]. *Chirurg*. 2004;75:967–975. German.

18. Amiot LP, Lang K, Putzier M, et al. Comparative results between conventional and computer-assisted pedicle screw installation in the thoracic, lumbar, and sacral spine. *Spine*. 2000;25:606–614.
19. Mirza SK, Wiggins GC, Kuntz C 4th, et al. Accuracy of thoracic vertebral body screw placement using standard fluoroscopy, fluoroscopic image guidance, and computed tomographic image guidance: A cadaver study. *Spine*. 2003;28:402–413.
20. Assaker R, Reynolds N, Vinchon M, et al. Transpedicular screw placement: Image-guided versus lateral-view fluoroscopy: In vitro simulation. *Spine*. 2001;26:2160–2164.
21. Davne SH, Myers DL. Complications of lumbar spinal fusion with transpedicular instrumentation. *Spine*. 1992;17(suppl 6):S184–S189.
22. West JL 3rd, Ogilvie JW, Bradford DS. Complications of the variable screw plate pedicle screw fixation. *Spine*. 1991;16:576–579.
23. Youkilis AS, Quint DJ, McGillicuddy JE, et al. Stereotactic navigation for placement of pedicle screws in the thoracic spine. *Neurosurgery*. 2001;48:771–779.
24. Wang MY, Kim KA, Liu CY, et al. Reliability of three-dimensional fluoroscopy for detecting pedicle screw violations in the thoracic and lumbar spine. *Neurosurgery*. 2004;54:1138–1143.
25. Hott JS, Deshmukh VR, Klopfenstein JD, et al. Intraoperative Iso-C C-arm navigation in craniocervical surgery: The first 60 cases. *Neurosurgery*. 2004;54:1131–1137.
26. Kalfas IH. Image-guided spinal navigation. *Techn Neurosurg*. 2003;8:47–55.
27. Haberland N, Ebmeier K, Grunewald JP, et al. Incorporation of intraoperative computerized tomography in a newly developed spinal navigation technique. *Comput Aid Surg*. 2000;5:18–27.
28. Rampersaud YR, Simon DA, Foley KT. Accuracy requirements for image-guided spinal pedicle screw placement. *Spine*. 2001;26:352–359.
29. Gebhard F, Kraus M, Schneider E, et al. [Radiation dosage in orthopedics—A comparison of computer-assisted procedures]. *Unfallchirurg*. 2003;106:492–497. German.
30. Foley KT, Holly LT, Schwender JD. Minimally invasive lumbar fusion. *Spine*. 2003;28(suppl 15):S26–S35.