

Clinical Study

RhBMP-2-induced radiculitis in patients undergoing transforaminal lumbar interbody fusion: relationship to dose

Alan T. Villavicencio, MD^{a,b}, Sigita Burneikiene, MD^{a,b,*}

^aBoulder Neurosurgical Associates, 4743 Arapahoe Ave, Suite 202, Boulder, CO 80303, USA

^bJustin Parker Neurological Institute, 4743 Arapahoe Ave, Suite 202, Boulder, CO 80303, USA

Received 21 October 2015; revised 2 May 2016; accepted 21 June 2016

Abstract

BACKGROUND CONTEXT: Recombinant human bone morphogenetic protein-2 (rhBMP-2) remains the primary synthetic osteoinductive material used in spinal fusion surgery today. The early inflammation reaction to rhBMP-2 manifesting with radicular symptoms has been previously reported in patients undergoing transforaminal lumbar interbody fusion (TLIF). There is a disagreement with regard to the factors affecting its occurrence and whether such symptoms are dose dependent.

PURPOSE: The purpose of this analysis was to determine the incidence of rhBMP-2-induced radiculitis and its relationship to dose.

STUDY DESIGN/SETTING: A retrospective cohort analysis was performed of the prospectively collected data.

PATIENT SAMPLE: All consecutive patients (n=204) who underwent one- or two-level TLIF and instrumented posterolateral fusion with an off-label rhBMP-2 use were included in this analysis.

OUTCOME MEASURES: The patients who developed new radicular symptoms after initial improvement postoperatively and had sterile fluid collections indicative of inflammatory process, or in the absence of any structural abnormalities that would explain these symptoms on imaging studies, were deemed to have rhBMP-2-induced radiculitis.

METHODS: Magnetic resonance imaging (MRI) scans were obtained for all patients who developed postoperative radicular symptoms. Correlations between the total rhBMP-2 dose, dose per spinal level, and incidence of radiculitis were evaluated while controlling for age, sex, number of TLIF levels, and surgeon.

RESULTS: The incidence of postoperative radiculitis was 11.3% (23 out of 204). The average total rhBMP-2 dose was 4.9 mg (range=2.1–12) and the average dose per spinal level was 3.8 mg (range=1.05–12). Logistic regression analysis did not identify any significant correlations between the rhBMP-2 doses and the incidence of radiculitis (p=.6).

CONCLUSION: The incidence of rhBMP-2-induced radiculitis in patients undergoing TLIF is quite high, but there were no dose-related correlations found. The study, however, cannot rule out a possibility that a larger variation in bone morphogenetic protein (BMP) doses could still be a factor in the development of rhBMP-2-associated radiculitis. © 2016 Elsevier Inc. All rights reserved.

Keywords:

Complications; Incidence; Radiculitis; Recombinant human bone morphogenetic protein-2; RhBMP-2; Transforaminal lumbar interbody fusion

FDA device/drug status: Not approved for this application (rhBMP-2).

Author disclosures: **ATV:** Physician-owned Distributorship: Leading Edge Spinal Implants (F), outside the submitted work; Board of Directors: Justin Parker Neurological Institute (Nonfinancial), outside the submitted work; Scientific Advisory Board/Other Office: NASS Educational Council Committee (Nonfinancial), AANS Joint Sponsorship Council Member (Nonfinancial), outside the submitted work; Research Support (Investigator Salary, Staff/Materials, amount received was towards investigator salary and/or staff/materials.): Globus (C, Paid to the institution), Profibrix

(F, Paid to the institution), Covidien (D, Paid to the institution), Grifols (D, Paid to the institution), outside the submitted work. **SB:** Nothing to disclose.

The disclosure key can be found on the Table of Contents and at www.TheSpineJournalOnline.com.

* Corresponding author. Boulder Neurosurgical Associates, 4743 Arapahoe Ave, Suite 202, Boulder, CO 80303, USA. Tel.: +1-303-938-5700; fax: +1-303-998-0007.

E-mail address: sigitab@bnasurg.com (S. Burneikiene)

Introduction

Recombinant human bone morphogenetic protein-2 (rhBMP-2) (InFuse; Medtronic Sofamor Danek, Memphis, TN, USA) remains the primary synthetic osteoinductive material used in spinal fusion surgery today. Although the use of rhBMP-2 in posterior lumbar interbody fusions was not approved by Food and Drug Administration (FDA), North American Spine Society recommends its use in patients with poor-quality autogenous bone or those at high risk for non-union, which includes patients undergoing revision or multilevel surgeries, elderly patients with osteoporosis, those with previous radiation exposure, smokers, and patients with diabetes and hypertension [1]. This potentially only excludes younger patients undergoing primary one- or two-level fusions.

There have been multiple reports published in the literature on rhBMP-2-related complications in lumbar spine surgery, mainly heterotopic ossification, osteolysis, epidural cyst formation, seromas, and radiculitis [2–9]. These reports have been followed by other reports stating that these complications may be related to the higher doses used [7,9–11], but none of the studies published so far provide high-quality evidence of such correlations. There are also studies contradicting the assumption of the dose-response relationship [12–14]. These reports have not specifically evaluated bone morphogenetic protein (BMP)-induced radiculitis or were underpowered to detect any significant effects.

An optimal BMP-2 dose that would induce high-quality bone fusion and avoid complications in spine surgeries has not been established. The reported doses generally range from 1.4 to 12 mg [3,13,15] and up to 20 mg [12] per spinal level. The concentration of 1.5 mg/mL and a dosage of 4.2–12 mg/level initially approved by FDA was based on primate data and was limited to anterior lumbar interbody fusion with titanium-tapered cages [16]. A higher concentration of 2.0 mg/mL was also tested for posterolateral fusion, but was not approved due to increased cancer risk [17,18]. When analyzing the literature, it seems that the authors who reported postoperative radicular symptoms in patients undergoing lumbar interbody and posterolateral fusions used slightly higher doses of rhBMP-2 ranging from 4.2 to 12 mg per spinal level [5,9,19–24]. Meanwhile, Crandall et al [9] reported that there were no new radicular symptoms in patients who received ≤ 4 mg dose. The main purpose of this study was to determine the incidence of rhBMP-2-induced radiculitis and its relationship to dose.

Methods

A retrospective cohort analysis was performed of the prospectively collected data. All consecutive transforaminal lumbar interbody fusion (TLIF) with instrumented posterolateral fusion cases performed from March of 2011 to October of 2013 with an “off-label” rhBMP-2 use were reviewed. Inclusion criteria were as follows: patients undergoing surgery for

EVIDENCE & METHODS

Context

Chemical radiculitis induced by the use of BMP-2 has been recognized as one of the more common complications associated with the use of this device, especially in association with posterior interbody fusion procedures. The authors present a retrospective cohort analysis regarding the incidence of BMP-2-induced radiculitis at their center.

Contribution

The study included 204 patients, 23 of whom went on to develop a radiculitis. Given the limited number of patients with the outcome of interest, it was difficult for the authors to identify any statistically significant associations.

Implications

However the data used in this study may have been collected, retrospective review, sample limitations and the potential for selection and classification bias render the evidence presented here Level IV in nature. Findings can be used in patient counseling, particularly when it comes to the likelihood of developing a radiculitis and the natural history of this condition. The study is most likely underpowered to detect differences in the population with radiculitis and those without, nor can potential confounders be controlled for given the numbers available. The regression models used by the authors are likely overfit given that only 23 patients in their cohort developed a BMP-2-induced radiculitis.

—The Editors

degenerative spinal conditions; primary one- or two-level TLIFs; at least 12 months of follow-up available. Only one- and two-level TLIF cases were selected because higher per-level doses may be required to achieve multiple level fusions [12]. Indications for surgery included degenerative disc disease, spondylosis, and spondylolisthesis. The patients undergoing lumbar fusions for trauma or cancer were excluded from this analysis. All patients underwent at least 6 months of conservative treatment before surgery was recommended. Surgeries were performed using an open transforaminal approach. The surgical and rhBMP-2 application techniques were previously described [24].

The primary outcome measure was radicular symptoms identified in the postoperative period and developed within a few days to several weeks. Patients who developed new radicular symptoms after initial improvement postoperatively and who had sterile fluid collections indicative of inflammatory process, or in the absence of any structural abnormalities that would explain these symptoms on imaging studies, were deemed to have rhBMP-2-induced radiculitis. Magnetic resonance imaging scans were obtained for all patients who developed postoperative radicular symptoms.

The patients were followed postoperatively at 7–14 days, 3, 6, 12, and 24 months. Data were collected on age, gender, spinal levels treated, postoperative radicular symptoms, total rhBMP-2 dose, and dose per spinal level. Correlations between the total rhBMP-2 dose, dose per spinal level, and incidence of radiculitis were evaluated using logistic regression analysis while controlling for age, sex, number of TLIF levels, and surgeon.

Results

A total of 204 patients who met the inclusion criteria were selected for further analysis. The incidence of postoperative radiculitis according to the established criteria was 11.3% (23 out of 204). There were 122 (59.8%) female and 82 (40.2%) male patients whose mean age was 59.0 years (range=28–88). Selected demographic and surgical patients characteristics are presented in Table 1. These characteristics were compared between two patient groups divided accordingly depending on the absence (Group I) or presence (Group II) of postoperative radicular symptoms. There were no statistically significant differences between the groups with respect to age, sex, or spinal levels.

Surgeries were performed by four different surgeons at a single institution with the following case distribution: 89, 72, 22, and 21. The rhBMP-2 dose was selected based on surgeon preferences with a tendency to use lower doses in the second part of the study (total dose 5.7 mg vs. 4.1 mg, $p=.0001$). The average total rhBMP-2 dose was 4.9 mg (range=2.1–12, standard deviation [SD]=2.8) and the average dose per spinal level was 3.8 mg (range=1.05–12, SD=1.9). Although, slightly higher average doses were used in patients who developed BMP-induced radiculitis, there were no statistically significant differences compared with the patients who did not (Table 2). Logistic regression analysis did not identify any significant correlations between the rhBMP-2 doses and the incidence of radiculitis ($p=.6$), after controlling for age, sex, number of TLIF levels, and surgeon.

Table 1

Selected patient demographic and surgical characteristics. Values are presented as means (ranges, or percentages) when appropriate. Student t tests were used for calculations except when noted*, in which case the chi square test with Pearson correlation was performed. Group I—absence of radicular symptoms; Group II—presence of postoperative radicular symptoms; TLIF—transforaminal lumbar interbody fusion

	Group I, n=181	Group II, n=23	p value
Age (years)	58.8 (28 – 88)	59.9 (36 – 80)	.69
Female/male ratio	76/105	6/17	.18*
Levels (average/range)	1.3 (1 – 2)	1.4 (1 – 2)	.46
One-Level TLIF	124 (68.5%)	14 (60.9%)	.85*
L3/L4	8 (4.4%)	1 (4.4%)	
L4/L5	77 (42.5%)	8 (34.8%)	
L5/S1	39 (21.6%)	5 (21.7%)	
Two-Level TLIF	57 (31.5%)	9 (39.1%)	
L3/L4, L4/L5	18 (9.9%)	4 (17.4%)	
L4/L5, L5/S1	39 (21.6%)	5 (21.7%)	

Table 2

RhBMP-2 doses. Values are presented as means (ranges). Student t tests were used for calculations

	Group I, n=181	Group II, n=23	p value
Total dose (mg)	4.8 (2.1 –12)	5.5 (2.1 –12)	.29
Dose per level (mg)	3.7 (1.05–12)	4.1 (1.05–12)	.37

Based on clinical symptoms and postoperative magnetic resonance imaging studies, the mechanism of postoperative BMP-induced radicular symptoms could be divided into two categories: inflammatory non-compressive radiculitis ($n=10$) and symptoms caused by sterile fluid collections indicative of inflammatory process ($n=13$). All patients developed symptoms within the first several weeks postoperatively and either underwent conservative treatment including steroid injections, anti-inflammatory medications, or incision, and drainage ($n=2$) was performed. The symptoms resolved within 3 months in the majority of patients. This study did not specifically evaluate fusion, but one patient in each group had pseudoarthrosis.

Case study 1

A 36-year-old female patient presented with L5/S1 degenerative disc disease and grade II spondylolisthesis. She underwent one-level TLIF surgery, and 4.2 mg of rhBMP-2 was used. Initially symptom free after surgery, 2 weeks later, she reported numbness and shooting pain down both lower extremities, more so on the right side. Magnetic resonance imaging scan was performed, which demonstrated fluid collection in the right L5/S1 foramen and adjacent to the TLIF graft (Figure). She was treated with methylprednisolone and had improvement of her symptoms by 6 months postoperatively.

Case study 2

A 62-year-old male patient was initially diagnosed with advanced degenerative disc disease and L4/L5 disc herniation, severe right L4/L5 and left L3/L4 foraminal stenosis, and bilateral recess and central canal stenosis at L3/L4. He

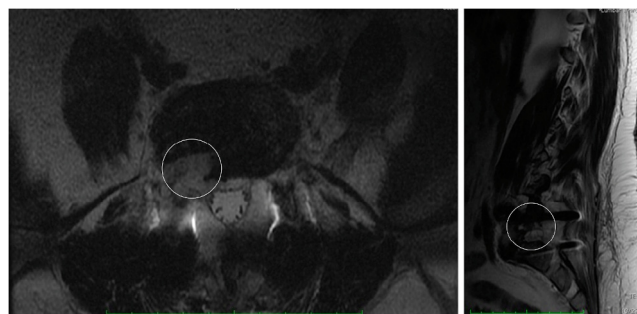


Figure. Contrast-enhanced T1-weighted magnetic resonance (MR) images of the lumbar spine, axial (Left) and sagittal (Right) views. The white circle indicates a moderate amount of fluid (7 cm×1.0 cm×0.7 cm) surrounding the thecal sac and posterior to the right TLIF graft extending into the right neural foramen.

underwent a two-level TLIF and posterolateral fusion at L3–L5 with 4.2 mg of rhBMP-2 and decompression of the neural foramen bilaterally. Initially doing well after surgery, 6 days after surgery, he developed a different type of pain in his right buttock and right lateral thigh. Magnetic resonance imaging was performed, and it did not reveal any structural abnormalities responsible for these symptoms. He was treated conservatively, and symptoms improved significantly by 3 months follow-up appointment.

Discussion

According to the systematic review published in 2010 [25], “the incidence of BMP-associated radiculopathy after lumbar fusion is poorly characterized from the literature published to date.” The incidence of postoperative radiculitis reported in patients undergoing lumbar interbody or posterolateral fusions ranged from 1% to 25% [5,9,12,20–22,26], and we have previously reported a 12.7% incidence for a different cohort of patients in whom rhBMP-2 was used in conjunction with TLIF [24].

The first paper reporting postoperative lumbar radiculitis attributed to BMP use was published in 2009 by Mindea et al [22]. A total of 4 out of 35 (11.4%) patients undergoing minimally invasive TLIF surgery had radicular symptoms. The authors believed that higher dose, insertion technique, overpacking the interbody device, and not irrigating the surgical area may have potentially been the contributing factors along with such structural etiologies as medial pedicle screw malpositioning or traction injuries. The patients had complete resolution of symptoms within 6 weeks. Rihn et al [5] retrospectively reviewed complications in single-level TLIF surgeries, in which either BMP (n=86) or iliac crest autograft was used (n=33). Only 3% of patients developed radicular symptoms in the iliac crest autograft group compared with 14% in patients who received BMP. Postoperative radiculitis was defined by worsening leg pain following surgery in a dermatomal distribution. Although the authors reported a higher new postoperative radiculitis rate associated with BMP use (14%), four out of eight patients had other identifiable causes that would exclude neurogenic inflammation as the cause for postoperative symptoms. The much lower rate in the control group and reduced rate of postoperative radiculitis in the patients who subsequently received hydrogen sealant to preclude inadvertent local spread indicates that at least some of these patients may have had inflammatory reactions to BMP.

RhBMP-2-induced radicular symptoms after initial improvement postoperatively develop within 1–4 days [22,27], the first 2 weeks [5], or even 6 weeks [28]. Although the symptoms of non-compressive radiculitis are transient and usually resolve within 6 weeks [22], it can take up to 6 months [12]. Being a diagnosis of exclusion, it may require conducting multiple diagnostic tests, which is associated with increased resource utilization not to mention patient frustration.

This study determined the incidence of rhBMP-2-induced radiculitis in patients undergoing TLIF with posterolateral

fusion and supplemental fixation. The 11.3% incidence of radiculitis was in the range of the previously reported incidence of 1% to 25%. In addition, our analysis demonstrated that there were no correlations between the occurrences of radiculitis and higher rhBMP-2 doses used.

Only two studies so far analyzed dose relationships of BMP-induced complications [9,12], but the occurrence rates for postoperative radiculitis were very low (1%), therefore these studies were most likely underpowered to detect significant effects. Regardless, the results of our study were consistent with the findings of Mesfin et al [12]. The authors retrospectively analyzed prospectively collected data on 502 idiopathic or degenerative spinal deformity cases undergoing long fusion surgeries with an average rhBMP-2 dose of 115 mg (range=40–351 mg). Four out of five patients who complained of postoperative radicular symptoms had TLIF procedure performed. A total of five (1%) patients developed radiculopathy symptoms, but the authors did not find a significant correlation with BMP dosage. On the contrary, Crandall et al [9] retrospectively analyzed BMP dose-related complications in 509 consecutive patients undergoing TLIF, and the authors argued that 4 mg is an adequate dose to achieve intervertebral fusion and avoid BMP-related complications. However, the reported postoperative radiculitis occurrence rate was also low (5 out of 509 patients) and, as described in the paper, the BMP role was uncertain in two patients who had ectopic bone formation or surgical technique (inadequate bone backfill) was most likely responsible for the symptoms in another two. They have not reported any patients with non-compressive radiculitis symptoms. Another study by Rowan et al [26] reported a very high rate (17.2%) of postoperative non-compressive transient radiculitis, which was strongly associated with BMP use (odds ratio=2.33), but the authors have not performed any dose-response assessments.

It is possible that such amplified inflammatory reactions to BMP related to increased macrophage activity within the dorsal root ganglia [29] and clinically manifesting as transient radiculitis are not dose dependent, because BMP-2-induced complications were reported when a very low dose of 1.4 mg per level was used in minimally invasive TLIF or PLIF surgeries [30]. We believe that such factors as concentration, containment, and surgical technique may be playing a more significant role in avoiding the direct induction of neurogenic inflammation on nerve roots, dorsal root ganglia, large nerves, and autonomic plexuses [7,31]. The surgical site BMP concentration is affected by individual clearance rate and vascularity of the surrounding environment [25], as opposed to just the dose that was applied initially. The presence of posterior longitudinal ligament and posterior annulus, which prevents the neurological structures from direct contact with BMP in anterior lumbar interbody fusions, explains the fact why non-compressive radiculitis symptoms were never reported in the original FDA rhBMP-2 trials. And finally, in vivo studies are exploring different carriers [32–34] or BMP-binding proteins [35] for safer and more efficient fusion induction.

Prevention

Although we did not find that higher rhBMP-2 doses used in TLIF surgeries lead to a higher incidence of transient radiculitis, caution should be used, and selection should be made for each patient individually based, among other things, on the criteria provided by North American Spine Society [1]. The technique of rhBMP-2 application is very important in maximizing containment within the intervertebral space and preventing BMP-induced complications. Several methods were suggested. Rihn et al [5] proposed the use of hydrogen sealant over the posterior annulotomy site, posterior to the interbody cage, over the exposed dura and nerve roots to preclude inadvertent local spread. They demonstrated a significant decrease (20.4%–5.4%) in postoperative radiculitis using this technique. Lykissas et al [36] described a protocol adopted at their institution, which included local 10-mg dexamethasone administration, along with cautious handling, copious irrigation, and soaking the carrier for at least 45 minutes to increase BMP-2 retention. Crandall et al [9] placed BMP-soaked sponges anterior and contralateral to the side of TLIF, inserted the cage, and then packed local autograft bone around the cage. They also selected shorter cages, allowing more room for autograft bone and preventing BMP from leaking into the spinal canal. We have previously reported a method in a study describing our first 74 consecutive patients [24]. We place BMP-soaked sponge anteriorly and create layers of barriers, which consist of a layer of autograft bone, structural allograft(s), and more autograft or allograft cancellous bone.

Limitations

There are multiple other sources for postoperative radicular pain, including incomplete decompression, stenosis resulting from hematoma, cyst or scar tissue, infection, hardware, or implant-related complications, which are easier to exclude than non-compressive causes such as traction injury or BMP-induced radiculitis. The former diagnosis in this study was based on the absence of any other potential morphological causes or presence of sterile fluid collections indicative of inflammatory process on imaging studies. The radicular symptoms usually manifested in a new location, also temporal relationship from rhBMP-2 use and the development of symptoms helped to define the etiology. The patients became symptomatic after a week or within the first several weeks after initial postoperative relief of radicular symptoms, so the timing was inconsistent with traction injury. But it is hard to make a definitive diagnosis based on patient history and symptomatic criteria, and often, it remains the diagnosis of exclusion after all other possibilities have been considered.

A control group in our study was not available because nearly all of our patients who undergo TLIF fusions receive rhBMP-2 within a relatively narrow range of 2.1–12 mg. Considering these limitations and retrospective nature of the study, definite conclusions regarding dose-response relationship between radicular symptoms and the use of BMP should be

made cautiously. The study results reiterate the fact that the optimal rhBMP-2 dose in lumbar spine surgeries remains unclear. Prospective, randomized, FDA-controlled clinical trials are needed to determine optimal rhBMP-2 doses and associated complications in TLIF surgeries.

Conclusion

The incidence of rhBMP-2-induced radiculitis in patients undergoing TLIF was quite high (11.3%), but there were no dose-related correlations found. The study, however, cannot rule out a possibility that a larger variation in BMP doses could still be a factor in the development of rhBMP-2-associated radiculitis.

References

- [1] North American Spine Society. NASS coverage policy recommendations. Recombinant human bone morphogenetic protein (rhBMP-2). 2014.
- [2] McClellan JW, Mulconrey DS, Forbes RJ, Fullmer N. Vertebral bone resorption after transforaminal lumbar interbody fusion with bone morphogenetic protein (rhBMP-2). *J Spinal Disord Tech* 2006;19:483–6.
- [3] Chrastil J, Low JB, Whang PG, Patel AA. Complications associated with the use of the recombinant human bone morphogenetic proteins for posterior interbody fusions of the lumbar spine. *Spine* 2013;38:E1020–7.
- [4] Joseph V, Rampersaud YR. Heterotopic bone formation with the use of rhBMP2 in posterior minimal access interbody fusion: a CT analysis. *Spine* 2007;32:2885–90.
- [5] Rihn JA, Patel R, Makda J, Hong J, Anderson DG, Vaccaro AR, et al. Complications associated with single-level transforaminal lumbar interbody fusion. *Spine J* 2009;9:623–9.
- [6] Cahill KS, Chi JH, Day A, Claus EB. Prevalence, complications, and hospital charges associated with use of bone-morphogenetic proteins in spinal fusion procedures. *JAMA* 2009;302:58–66.
- [7] Wong DA, Kumar A, Jatana S, Ghiselli G, Wong K. Neurologic impairment from ectopic bone in the lumbar canal: a potential complication of off-label PLIF/TLIF use of bone morphogenetic protein-2 (BMP-2). *Spine J* 2008;8:1011–18.
- [8] Haid RW Jr, Branch CL Jr, Alexander JT, Burkus JK. Posterior lumbar interbody fusion using recombinant human bone morphogenetic protein type 2 with cylindrical interbody cages. *Spine J* 2004;4:527–38 discussion 38–9.
- [9] Crandall DG, Revella J, Patterson J, Huish E, Chang M, McLemore R. Transforaminal lumbar interbody fusion with rhBMP-2 in spinal deformity, spondylolisthesis, and degenerative disease—part 2: BMP dosage-related complications and long-term outcomes in 509 patients. *Spine* 2013;38:1137–45.
- [10] Shields LB, Raque GH, Glassman SD, Campbell M, Vitaz T, Harpring J, et al. Adverse effects associated with high-dose recombinant human bone morphogenetic protein-2 use in anterior cervical spine fusion. *Spine* 2006;31:542–7.
- [11] Tumialan LM, Pan J, Rodts GE, Mummaneni PV. The safety and efficacy of anterior cervical discectomy and fusion with polyetheretherketone spacer and recombinant human bone morphogenetic protein-2: a review of 200 patients. *J Neurosurg Spine* 2008;8:529–35.
- [12] Mesfin A, Buchowski JM, Zebala LP, et al. High-dose rhBMP-2 for adults: major and minor complications: a study of 502 spine cases. *J Bone Joint Surg Am* 2013;95:1546–53.
- [13] Bess S, Line BG, Lafage V, Schwab F, Shaffrey CI, Hart RA, et al. Does recombinant human bone morphogenetic protein-2 use in adult spinal deformity increase complications and are complications associated

- with location of rhBMP-2 use? A prospective, multicenter study of 279 consecutive patients. *Spine* 2014;39:233–42.
- [14] Singh K, Ahmadinia K, Park DK, Nandyala SV, Marquez-Lara A, Patel AA, et al. Complications of spinal fusion with utilization of bone morphogenetic protein: a systematic review of the literature. *Spine* 2014;39:91–101.
- [15] Rahman RK, Buchowski JM, Stephens B, Dorward IG, Koester LA, Bridwell KH. Comparison of TLIF with rhBMP-2 versus no TLIF and higher posterolateral rhBMP-2 dose at L5-S1 for long fusions to the sacrum with sacropelvic fixation in patients with primary adult deformity. *Spine* 2013;38:2264–71.
- [16] Summary of Safety and Effective Data premarket approval application P000058. Rockville, MD: 2002. FDA. InFUSE Bone Graft/LT-CAGE Lumbar Tapered Fusion Device.
- [17] Dimar JR 2nd, Glassman SD, Burkus JK, Pryor PW, Hardacker JW, Carreon LY. Clinical and radiographic analysis of an optimized rhBMP-2 formulation as an autograft replacement in posterolateral lumbar spine arthrodesis. *J Bone Joint Surg Am* 2009;91:1377–86.
- [18] Food and Drug Administration (FDA) Summary of Safety and Effectiveness Data (SSED) for P050036 Medtronic's AMPLIFY™ rhBMP-2 matrix. 2010. Orthopaedic and Rehabilitation Devices Advisory Panel. <http://www.fda.gov/downloads/advisorycommittees/committeesmeetingmaterials/medicaldevices/medicaldevicesadvisorycommittee/orthopaedicandrehabilitationdevicespanel/ucm20079.pdf>. Accessed July 8, 2016.
- [19] Muchow RD, Hsu WK, Anderson PA. Histopathologic inflammatory response induced by recombinant bone morphogenetic protein-2 causing radiculopathy after transforaminal lumbar interbody fusion. *Spine J* 2010;10:e1–6.
- [20] Lubelski D, Abdullah KG, Steinmetz MP, Alvin MD, Nowacki AS, Chakka S, et al. Adverse events with the use of rhBMP-2 in thoracolumbar and lumbar spine fusions: a 9-year institutional analysis. *J Spinal Disord Tech* 2015;28:E277–83.
- [21] Owens K, Glassman SD, Howard JM, Djurasovic M, Witten JL, Carreon LY. Perioperative complications with rhBMP-2 in transforaminal lumbar interbody fusion. *Eur Spine J* 2011;20:612–17.
- [22] Minda SA, Shih P, Song JK. Recombinant human bone morphogenetic protein-2-induced radiculitis in elective minimally invasive transforaminal lumbar interbody fusions: a series review. *Spine* 2009;34:1480–4 discussion 5.
- [23] Rihn JA, Makda J, Hong J, Patel R, Hilibrand AS, Anderson DG, et al. The use of RhBMP-2 in single-level transforaminal lumbar interbody fusion: a clinical and radiographic analysis. *Eur Spine J* 2009;18:1629–36.
- [24] Villavicencio AT, Burneikiene S, Nelson EL, Bulsara KR, Favors M, Thramann J. Safety of transforaminal lumbar interbody fusion and intervertebral recombinant human bone morphogenetic protein-2. *J Neurosurg Spine* 2005;3:436–43.
- [25] Mroz TE, Wang JC, Hashimoto R, Norvell DC. Complications related to osteobiologics use in spine surgery: a systematic review. *Spine* 2010;35(Suppl. 9):S86–104.
- [26] Rowan FE, O'Malley N, Poynton A. RhBMP-2 use in lumbar fusion surgery is associated with transient immediate post-operative leg pain. *Eur Spine J* 2012;21:1331–7.
- [27] Sanfilippo JA, Lee JY, Rihn J, Albert TJ, Hilibrand AS. BMP-2 causes increased postoperative radiculitis following TLIF. *Spine J* 2007;5S:6S–6S.
- [28] Licina P. Early complications associated with BMP in lumbar interbody fusions. Spine Society of Australia, Annual Scientific Meeting; 2008; Adelaide, Australia. *J Bone Joint Surg BR* 91-B SUPP III:437.
- [29] Dmitriev AE, Lehman RA Jr, Symes AJ. Bone morphogenetic protein-2 and spinal arthrodesis: the basic science perspective on protein interaction with the nervous system. *Spine J* 2011;11:500–5.
- [30] Mannion RJ, Nowitzke AM, Wood MJ. Promoting fusion in minimally invasive lumbar interbody stabilization with low-dose bone morphogenetic protein-2—but what is the cost? *Spine J* 2011;11:527–33.
- [31] Heggenes MH. Important considerations on bone morphogenetic protein-2 and neuroinflammation. *Spine J* 2011;11:506.
- [32] Lee JW, Lee S, Lee SH, Yang HS, Im GI, Kim CS, et al. Improved spinal fusion efficacy by long-term delivery of bone morphogenetic protein-2 in a rabbit model. *Acta Orthop* 2011;82:756–60.
- [33] Majid K, Tseng MD, Baker KC, Reyes-Trocchia A, Herkowitz HN. Biomimetic calcium phosphate coatings as bone morphogenetic protein delivery systems in spinal fusion. *Spine J* 2011;11:560–7.
- [34] La WG, Kang SW, Yang HS, Bhang SH, Lee SH, Park JH, et al. The efficacy of bone morphogenetic protein-2 depends on its mode of delivery. *Artif Organs* 2010;34:1150–3.
- [35] Tian H, Li CS, Scott TP, Montgomery SR, Phan K, Lao L, et al. Secreted phosphoprotein 24 kD inhibits nerve root inflammation induced by bone morphogenetic protein-2. *Spine J* 2015;15:314–21.
- [36] Lykissas MG, Aichmair A, Sama AA, Hughes AP, Lebl DR, Cammisa FP, et al. Nerve injury and recovery after lateral lumbar interbody fusion with and without bone morphogenetic protein-2 augmentation: a cohort-controlled study. *Spine J* 2014;14:217–24.